A randomized controlled trial evaluating the benefit of cone beam CT guidance to electromagnetic navigation bronchoscopy for the diagnosis of pulmonary nodule

Benjamin Bondue[1], Olivier Taton[1], Fadi Tannouri[2], N. Van De Velde[1], Myriam Remmelink[3], Dimitri Leduc[1]

[1] Department of Pneumology, Hôpital Erasme, Université libre de Bruxelles, Brussels, Belgium
[2] Department of Radiology, Hôpital Erasme, Université libre de Bruxelles, Brussels, Belgium
[3] Department of Pathology, Hôpital Erasme, Université libre de Bruxelles, Brussels, Belgium

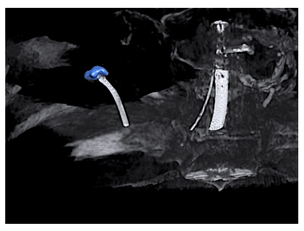

Introduction

- Low diagnostic yield of TBB for peripheral nodules of less than 2 cm of diameter (14%) [1]
- Electromagnetic navigation bronchoscopy (ENB) increases the diagnostic yield (DY ranging from 52% to 72,9%) [2-5].
- In addition, use of CBCT allows:
  - Real-time control of the position of the ENB catheter
  - Enhanced fluoroscopy
  - Trans-parenchymal access (CrossCountry catheter)

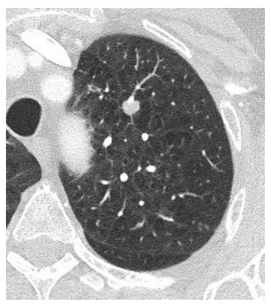

ENB

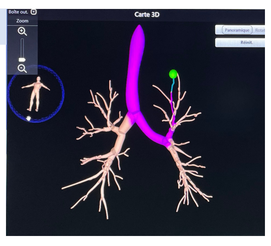

CBCT

CBCT acquisition

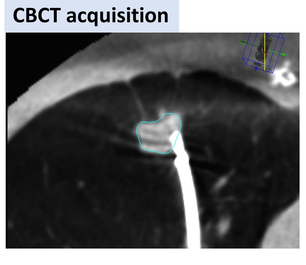

Enhanced fluoroscopy

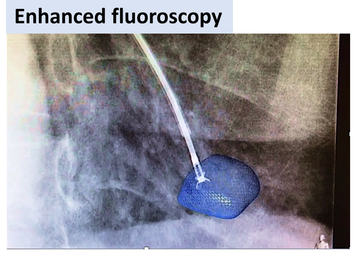

Trans-parenchymal access

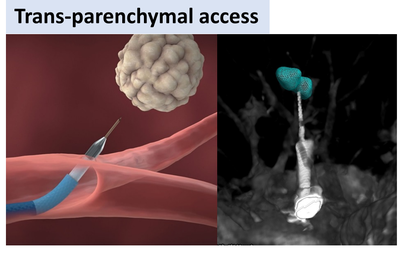

Aim of the study

To assess the added value of using CBCT guidance in addition to ENB for the diagnosis of peripheral nodules.

Methods

- Monocentric prospective randomized trial conducted between February 2020 and December 2021 in an academic hospital (Erasme hospital, Brussels, Belgium).
  - Lesion of 30 mm diameter max
  - Highly selected patients (no alternative)
  - Previous negative bronchoscopy in 40% of the cases

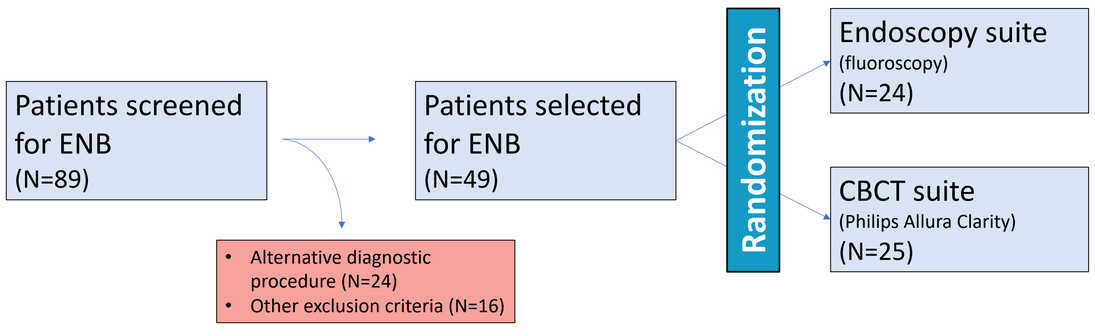

- For all procedures:
  - ENB (Medtronic SuperDimension platform)
  - Radial EBUS
  - Forceps biopsy (x6) (4fr, Boston Scientific)
  - Cryobiopsy (x1) (1,7mm, ERBE)
- Primary endpoint:
  - Diagnostic yield (specific histological diagnosis/all cases)
  - Diagnostic accuracy for malignancy (TP+TN/TP+TN+FP+FN)

Results

Patients and nodules characteristics		All (n=49)	Endoscopy (n=24)	CBCT (n=25)	P value
Age mean (SD)		65 (10)	65 (11)	64 (10)	0,864
Gender (woman) %		54	58	48	0,469
BMI mean (SD)		25 (4)	25 (4)	26 (4)	0,332
Smoking (tobacco) %					
	Active	18	21	16	0,662
	Past	64	58	68	0,483
	Never	18	21	16	0,662
PFT mean (SD)					
	% FEV	75 (21)	74 (21)	77 (20)	0,676
	% FVC	85 (20)	87 (16)	84 (23)	0,664
	% DLCO	60 (21)	64 (25)	56 (17)	0,269
sPAP (mmHg) mean (SD)		31 (6)	30 (7)	31 (6)	0,860
Size (mm) mean (SD)*		16,3 (5,3)	15,9 (4,6)	16,6 (6,0)	0,659
Type of nodule %					
	Solid	76	79	72	0,560
	Part-solid	14	12	16	0,726
	Non-solid	10	9	12	0,706
Bronchus sign %		39	37	40	0,858
Tangential bronchus %		24	33	16	0,158
Localisation %					
	RUL	39	29	48	0,176
	ML	6	8	4	0,527
	RLL	12	13	12	0,957
	LUL	29	29	28	0,928
	LLL	14	21	8	0,199

Lesion « reached » defined as:
- Abnormal histology
- Anatomical confiramtion of the position of the catheter in front or within the lesion (r-EBUS, CBCT, or fluoroscopy)

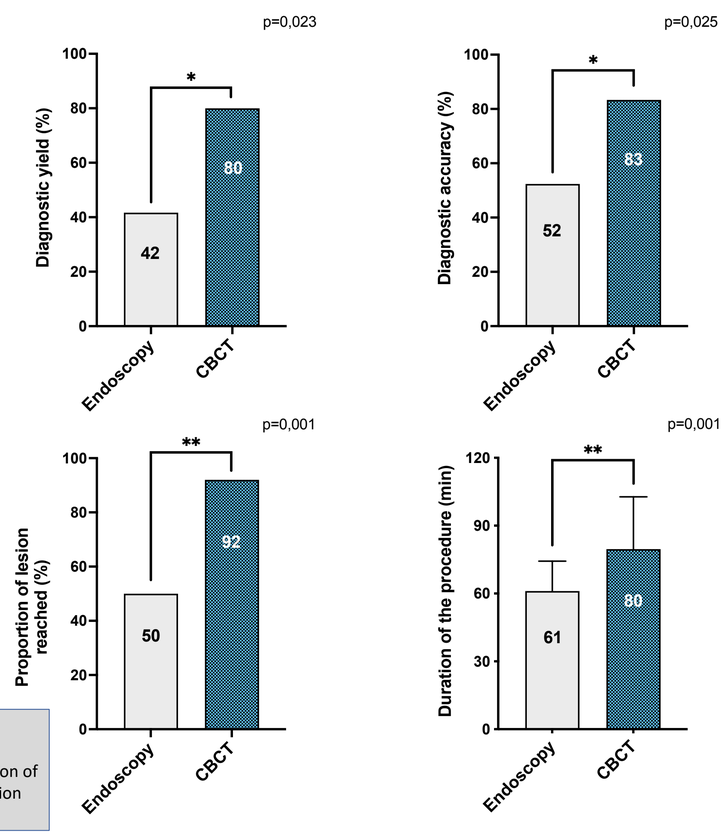

Secondary endpoints		All procedures	Endoscopy suite	CBCT suite	P value
Additional information from TBLC (unconclusive forceps TBB)		14% (6/42)	12,5% (3/24)	17% (3/18)	NS
Pneumothorax		6% (3/49)	8% (2/24)	4% (1/25)	NS
Bleeding	No or mild	90% (44/49)	83% (20/24)	96% (24/25)	NS
	Moderate	10% (5/49)	17% (4/24)	4% (1/25)	NS
	Severe	0% (0/49)	0% (0/24)	0% (0/25)	NS

CONCLUSIONS

- The use of CBCT guidance in addition to ENB significantly increases the diagnostic yield and diagnostic accuracy of TBB (forceps and cryo) for small size nodules (mean maximal diameter lower than 2 cm).
- No difference regarding severity of bleeding or the rate of pneumothorax is observed with respect to the limited number of participants.
- Duration of the procedure is slightly increased.

Disclosure:
BB received a grant from the Fonds Erasme to perform this study. BB also received consultancy fees and grants unrelated to this work from Boehringer Ingelheim and Hoffmann - La Roche.

References:

1. Baaklini WA, et al. Chest. 2000 Apr;117(4):1049-54.
2. Verhoeven RLJ, et al. J Bronchology Interv Pulmonol. 2021;28(1):60-69.
3. Gex G, et al. Respiration. 2014;87(2):165-176.
4. Wang Memoli JS, et al. Chest. 2012;142(2):385-393.
5. Folch EE, et al. J. Thorac. Oncol. 2019;14(3):445-458.